



Different Spectrum of Arrhythmia in Myocarditis: QT Interval Prolongation Followed to Supraventricular Tachycardia

Miyokarditte Farklı Spektrumda Aritmiler: Supraventriküler Taşikardiyi Takip Eden QT Uzaması

Different Spectrum of Arrhythmia in Myocarditis

Ebru Aypar¹, Eyup Aslan², Ahmet Sert², Dursun Odabas²

¹Department of Pediatric Cardiology, Hacettepe University, Faculty of Medicine, Ankara,
²Department of Pediatric Cardiology, Konya Training and Research Hospital, Konya, Turkey

Özet

Akut miyokardit, bebeklerde kardiyak disfonksiyon ve aritmiler ile komplike olabilen bir enfeksiyondur. Bu hastaların elektrokardiyografilerinde düşük voltaj QRS kompleksli sinus taşikardisi, T dalgası ve ST segment değişiklikleri, atriyal ve ventriküler taşikardi, atriyoventriküler blok ve QT süresinde uzama görülebilmektedir. Miyokarditte atriyal ve ventriküler aritmiler bildirilmiş olmasına rağmen bu aritmilerin birbirlerine geçiş göstermesi ile ilgili kısıtlı sayıda bildirim vardır. Viral miyokarditte supraventriküler taşikardi ile başvuran ve QT uzaması gelişen ve yeniden sinüs ritmine dönen bir bebek olgu sunuyoruz.

Anahtar Kelimeler

Miyokardit; Supraventriküler Taşikardi; Uzamış QT Süresi

Abstract

Acute myocarditis is an infection in infants which may be complicated by cardiac dysfunction and arrhythmias. Sinus tachycardia with low-voltage QRS complexes, T waves and ST-segment changes, atrial or ventricular tachycardia, atrioventricular block, QT interval prolongation on electrocardiogram (ECG) may be seen in patients with acute myocarditis. Although atrial or ventricular arrhythmias have been reported in myocarditis, there are limited reports of arrhythmias complicating with each other. We describe the case on an infant presented with supraventricular tachycardia complicating to the QT interval prolongation and back to the sinus rhythm in viral myocarditis.

Keywords

Myocarditis; Supraventricular Tachycardia; Prolonged QT Interval

DOI: 10.4328/JCAM.1494 Received: 25.12.2012 Accepted: 10.01.2013 Printed: 01.05.2016 J Clin Anal Med 2016;7(3): 408-10
Corresponding Author: Eyup Aslan, Department of Pediatric Cardiology, Konya Training and Research Hospital, 42080, Konya, Turkey.
T.: +90 3323236709 F.: +90 3323236723 E-Mail: doktor_eyup@myynet.com

Introduction

Acute myocarditis is an inflammatory disease of the heart muscle. Although causes from a number of infectious and non-infectious agents such as viruses, bacteria, protozoa, fungi, toxins, myocardial involvement in systemic diseases, acute myocarditis is often results from viral infection in childhood. Infants are most susceptible to myocarditis, probably because they lack cross-reacting immunity from few or no prior infections [1]. Cardiac manifestations in infants can range from an asymptomatic state to congestive heart failure or sudden death may occur. Electrocardiographic findings in myocarditis are very variable and may include sinus tachycardia, atrial or ventricular arrhythmias, heart block, diminished QRS voltages, QT interval prolongation and non-specific ST and T-wave changes [2]. We describe the case on an infant presented with supraventricular tachycardia complicating to the QT interval prolongation and back to the sinus rhythm in viral myocarditis.

Case Report

A 3-month-old boy was admitted with complaints of poor feeding, tachypnea and diarrhea lasting for two days. His past history was unremarkable. Physical examination revealed: body weight: 5000 grams (25-50 p), height: 66 cm (50 p), head circumference: 38.5 cm (25 p). He had regular tachycardia (pulse rate: 245/min) and his respiratory rate: 80/min, body temperature: 36.9 C°, blood pressure: 70/30 mmHg. His general state was poor; he had severe tachypnea and retraction of the breath muscles. He had 2/6 short systolic murmur in the mesocardiac area and liver was palpated as 5 cm on midclavicular line. A 12 lead ECG was consistent with supraventricular tachycardia (SVT) (heart rate: 245 beats/min, narrow QRS complex and absent of P waves) (Figure 1). Complete blood count, renal function, C-reactive protein, procalcitonin and serum electrolytes were normal except hypopotasemia 2.9 mEq/l (N: 3.5-5.1 mEq/l). Liver enzymes were elevated four times than normal (aspartate aminotransferase 150 U/l (N: 5-34 U/l), alanine aminotransferase 240 U/l (N: 0-55 U/l). His troponin I value was high as 0.41ng/ml (N: < 0.20 ng/ml). Viral serology tests (nasopharyngeal aspirate, stool i.e.) were normal. Infectious workups, including blood and urine cultures for bacteria, were negative. The echocardiography revealed LV systolic dysfunction (Ejection Fraction: 50%, Fraction Shortening: 26%) with enlarged LV dimension. A chest X-ray showed cardiomegaly (Figure 2). The patient was diagnosed as

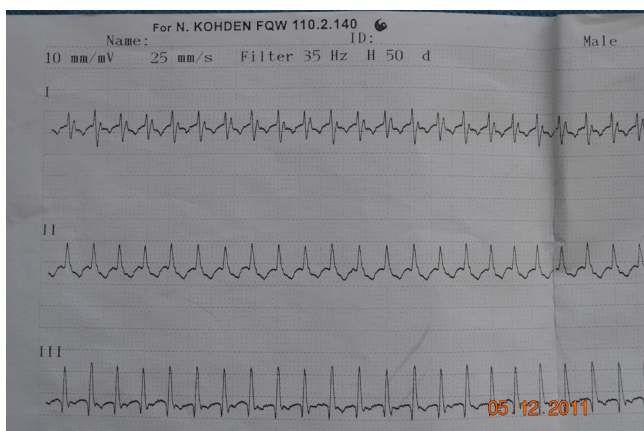


Figure 1. Electrocardiography shows supraventricular tachycardia (heart rate: 245 beats/min, narrow QRS complex and absent of P waves).

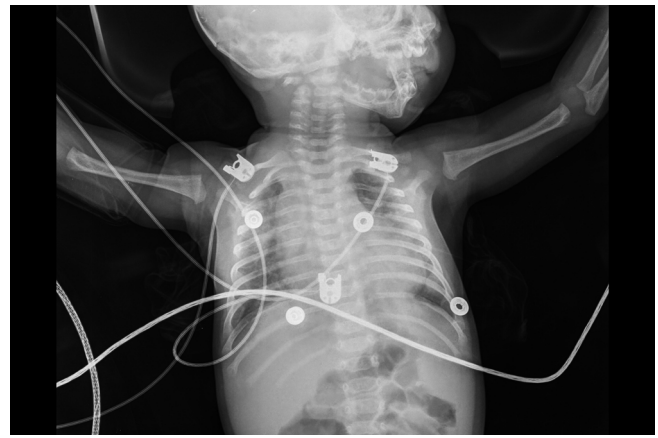


Figure 2. A chest X-ray showed cardiomegaly

SVT with viral myocarditis and bronchiolitis based on the clinical and laboratory findings.

At first, ice bag to the face was performed, but it was not successful. Afterwards, SVT reverted to sinus rhythm with intravenous adenosine (a dose of 100 µg per kg), but tachycardia recurred within ten minutes, which was terminated with adenosine (150 µg per kg) again. Intravenous immune globulin (2 gram per kg) was administered for presumed myocarditis and dobutamin was started (5 µg per kg per min) for cardiac heart failure. He had also given supportive treatment to the bronchiolitis. On admission day two, he had bradycardia with normal other vital functions. His electrocardiography revealed sinus bradycardia with heart rate 80 beats/min and cQT interval was 467 ms (Figure 3). Serum electrolytes and thyroid function tests were normal. There was no supraventricular or ventricular premature beat or tachycardia during follow-up. On admission day six, his ECG returned to sinus rhythm with normal cQT interval. Repeated ECG showed sinus rhythm with normal cQT interval. After discharge, 24-hour ECG showed no arrhythmia. The patient is followed up for a year with no complaints.

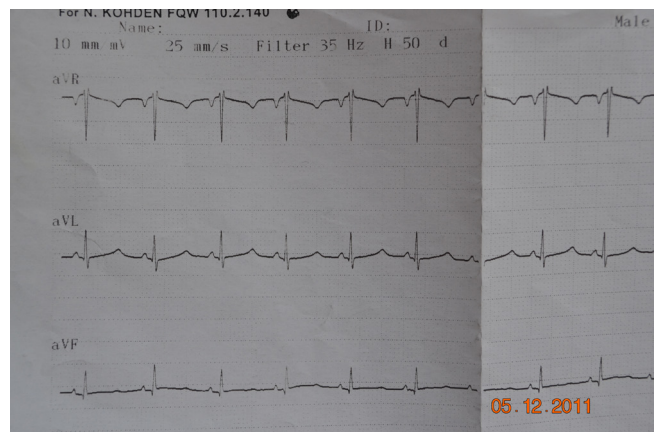


Figure 3. Electrocardiography with prolonged QT interval (467msn).

Discussion

The diagnosis of myocarditis requires high index of suspicion, because of different presentation from an asymptomatic state with only transient electrocardiographic changes to signs of fulminant cardiogenic shock. Electrocardiographic abnormalities are occurring commonly in myocarditis. Supraventricular, junctional or ventricular tachycardia were reported in different

aetiologies of myocarditis [3]. Additionally, there had been reported junctional ectopic tachycardia followed complete heart block associated with viral myocarditis [4] but to the best of our knowledge supraventricular tachycardia followed bradycardia with prolonged QT interval is the first described in the literature.

Supraventricular tachycardia is a common abnormality of heart rhythm in the paediatric patient, often presenting before the age of four months. The rate of the tachycardias ranges from 220 to 320 beats per minute in infants. The severity of symptoms is highly variable and depends on features including heart rate, duration of tachycardia, underlying heart disease and individual patient perception [5]. If the tachycardia sustained 6 to 12 hours, signs of congestive heart failure usually develop. Etheridge et al, [6] found that 30% of infants with SVT had signs and symptoms of congestive heart failure, at presented. Our case had tachycardia with poor appetite, tachypnea and hepatomegalia considered to congestive heart failure, which confirmed with ECG and echocardiography. His tachycardia might be for a long time.

QT interval prolongation can be seen, in myocarditis, endocrinopathies, drugs and electrolytes abnormalities [7]. Ramamurthy et al, [8] evaluated 20 patients with idiopathic myocarditis proven by endomyocardial biopsy. Their electrocardiograms were abnormal in all, with a prolonged QT interval being the commonest abnormality (14 patients). In our case, during the bradycardia with prolonged QT interval, electrolytes and thyroid function tests were normal. In our opinion, this electrocardiographic disturbance attributed to myocarditis. His bradycardia returned to sinus rhythm without specific treatment.

In conclusion, we would like to emphasize that clinicians should be aware of the possibility that cardiac arrhythmias might be differ with each other in myocarditis and should be followed up with caution and monitoring these patients closely.

Competing interests

The authors declare that they have no competing interests.

References

1. Hilinski JA. Myocarditis. In: Long SS, Pickering LK, Prober CG, editors. Principles and Practice of Pediatric Infectious Diseases. Third Edition. Philadelphia: Churchill Livingstone; 2008. Chapter 40.
2. Park MK. Pediatric Cardiology for Practitioners. Philadelphia: 5th ed. Mosby Elsevier; 2009. p. 360-64.
3. Pavithran S, Khatri S, Bagyaraj BA, Pandurangi UM, Kumar RS. Myocarditis presenting as junctional ectopic tachycardia. Indian Heart J. 2009; 61(3):288-9.
4. Maiers JA, Ebenroth ES Junctional ectopic tachycardia following complete heart block associated with viral myocarditis. Pediatr Cardiol. 2006; 27(3):367-8.
5. Medi C, Kalman JM and Freedman SB. Supraventricular tachycardia. MJA 2009; 190(5):255-60.
6. Etheridge SP, Judd VE. Supraventricular tachycardia in infancy: evaluation, management and follow-up. Arch Pediatr Adolesc Med 1999;153:267-71
7. Meyer JS, Mehdirdad A, Salem BI, Kulikowska A, Kulikowski P. Sudden Arrhythmia Death Syndrome: Importance of the Long QT Syndrome. Am Fam Physician 2003;68:483-8.
8. Ramamurthy S, Talwar KK, Goswami KC, Shrivastava S, Chopra P, Broor S. Clinical profile of biopsy proven idiopathic myocarditis. Int J Cardiol. 1993;41 (3) :225-32.

How to cite this article:

Aypar E, Aslan E, Sert A, Odabas D. Different Spectrum of Arrhythmia in Myocarditis: QT Interval Prolongation Followed to Supraventricular Tachycardia. J Clin Anal Med 2016;7(3): 408-10.